

JURNAL

# RESPIROLOGI

INDONESIA

Majalah Resmi Perhimpunan Dokter Paru Indonesia  
Official Journal of The Indonesian Society of Respiriology



*Pleural Fluid Leukocyte Level Test For Establishing Tuberculous Pleural Effusion in Patients with Exudative Pleural Effusion*

*Pulmonary Health of Traffic Policemen in Low Air-Polluted Bogor Area*

*Correlation Between Type 2 Diabetes Mellitus and Pulmonary Tuberculosis at Atma Jaya Hospital*

*Covid-19 Patient Condition at Early Pandemic in Jakarta Risk Factors Affecting Respiratory*

*Complaints and Impaired Lung Function of Palm Oil Mill Workers in the District of Kandis*

*Correlation Between Leukocyte Differential Counts with The Severity and Outcome of Coronavirus Disease 2019 (Covid-19) Patients in Jember*

*Correlation of Ceramic Dust Content in Workplace with Lung Function in Ceramics Industry Workers of X Company, Jabar, Medan*

*Exhaled Carbon Monoxide (eCO) and Serum CC16 Levels in Active Smokers*

*Case Report Tuberculosis of The Prostate: Findings of Post Transurethral Resection of Prostate (TURP) Procedure*

*Pediatric Hemoptysis*

# JURNAL RESPIROLOGI INDONESIA

Majalah Resmi Perhimpunan Dokter Paru Indonesia  
Official Journal of The Indonesian Society of Respiriology

---

## **SUSUNAN REDAKSI**

### **Penasehat**

M. Arifin Nawas  
Faisal Yunus  
Agus Dwi Susanto

### **Penanggung Jawab / Pemimpin Redaksi**

Fanny Fachrucha

### **Wakil Pemimpin Redaksi**

Winariani

### **Anggota Redaksi**

Feni Fitriani  
Amira Permatasari Tarigan  
Jamal Zaini  
Farih Raharjo  
Mia Elhidsi  
Ginangjar Arum Desianti  
Irandi Putra Pratomo

### **Sekretariat**

Shalzaviera Azniatinesa  
Suwondo  
SST : Surat Keputusan Menteri Penerangan RI  
No.715/SK/DitjenPPG/SST/1980 Tanggal 9 Mei 1980

### **Alamat Redaksi**

PDPI Jl. Cipinang Bunder, No. 19, Cipinang Pulo Gadung  
Jakarta Timur 13240 Telp: 02122474845  
Email : editor@jurnalrespirologi.org  
Website : <http://www.jurnalrespirologi.org>

### **Diterbitkan Oleh**

Perhimpunan Dokter Paru Indonesia (PDPI)  
Terbit setiap 3 bulan (Januari, April, Juli & Oktober)

### **Jurnal Respirologi Indonesia**

Akreditasi Peringkat 2  
Sesuai Keputusan Menteri Riset dan Teknologi/Kepala Badan  
Riset dan Inovasi Nasional Republik Indonesia  
Nomor: 200/M/KPT/2020 Tanggal 23 Desember 2020

# JURNAL RESPIROLOGI INDONESIA

Majalah Resmi Perhimpunan Dokter Paru Indonesia  
Official Journal of The Indonesian Society of Respiriology

VOLUME 41, NOMOR 3, Juli 2021

---

## DAFTAR ISI

---

### Artikel Penelitian

- Pleural Fluid Leukocyte Level Test For Establishing Tuberculous Pleural Effusion in Patients with Exudative Pleural Effusion* 156  
**Selvy Wulandari, Fajrinur Syahrani, Ade Rahmaini, Putri Chairani Eyanoeer**
- Pulmonary Health of Traffic Policemen in Low Air-Polluted Bogor Area* 161  
**Harris Abdullah, Jamal Zaini, Budhi Antariksa, Agus Dwi Susanto, Faisal Yunus**
- Correlation Between Type 2 Diabetes Mellitus and Pulmonary Tuberculosis at Atma Jaya Hospital* 170  
**Mario Steffanus, Anastasia Pratiwi Fodianto, Jessica Novia Hadiyanto**
- Covid-19 Patient Condition at Early Pandemic in Jakarta Risk Factors Affecting Respiratory* 174  
**Andika Chandra Putra, Wiwien Heru Wiyono, Mohammad Fahmi Alatas, Aulya Fairuz, Fransiska, Bettia Bermawi, Ratna Moniqa, Hendra Koncoro, Laurentius Aswin Pramono, Maria Edith Sulistio, Ramzi, Robert Sinto, Rachmat Hamonangan, C. Krismini Dwi Irianti, JB Endrotomo Sumargono**
- Complaints and Impaired Lung Function of Palm Oil Mill Workers in the District of Kandis* 180  
**Surya Hajar Fitria Dana, Indi Esha, Adrianison, Azizman Saad, Faisal Yunus, Ridha Restilla**
- Correlation Between Leukocyte Differential Counts with The Severity and Outcome of Coronavirus Disease 2019 (Covid-19) Patients in Jember* 187  
**Angga Mardro Raharjo, Eprila Darma Sari, Diana Chusna Mufida**
- Correlation of Ceramic Dust Content in Workplace with Lung Function in Ceramics Industry Workers of X Company, Mabar, Medan* 196  
**Endy Amos TH Sirait, Nuryunita Nainggolan, Amira Permatasari Tarigan, Putri Chairani Eyanoeer**
- Exhaled Carbon Monoxide (eCO) and Serum CC16 Levels in Active Smokers* 200  
**Fitri Indah Sari, Tri Wahyu Astuti, Teguh Rahayu Sartono, Garinda Alma Duta**
- ### Tinjauan Pustaka
- Case Report Tuberculosis of The Prostate: Findings of Post Transurethral Resection of Prostate (TURP) Procedure* 207  
**Kadek Mien Dwi Cahyani, Ni Made Dwita Yaniswari, Novitasari**
- Pediatric Hemoptysis* 214  
**Hana Khairina Putri Faisal, Faisal Yunus**

# Case Report Tuberculosis of The Prostate: Findings of Post Transurethral Resection of Prostate (TURP) Procedure

Kadek Mien Dwi Cahyani<sup>1</sup>, Ni Made Dwita Yaniswari<sup>2</sup>, Novitasari<sup>3</sup>

<sup>1</sup>Faculty of Medicine Udayana University, Bali

<sup>2</sup>Department of Pulmonology and Respiratory Medicine Wangaya Hospital, Bali

<sup>3</sup>Department of Pathology Anatomy Wangaya Hospital, Bali

## Abstract

**Background:** Prostate tuberculosis (PTB) is one of extrapulmonary tuberculosis which potentially has more frequent fatal complications and more severe quality of life deterioration. It is a very rare disease, with a prevalence of 2.6% of all urogenital tuberculosis (UGTB). Prostate tuberculosis may be a sexually transmitted disease and leads to sexual dysfunction.

**Case:** Male, 54 years old, with urinary retention, dysuria, flank pain in the last 1-month, recurrent urinary tract infection in the past 1 year and decrease body weight of 8 kg in 1 month. Physical examination demonstrates enlarged prostate. The patient was referred to Wangaya Hospital with benign prostate hyperplasia (BPH) and suspect malignancy. After underwent clinical and supporting examination, the patient underwent a TURP procedure. Histopathology examination revealed PTB. The patient was then treated with a first-line anti-tuberculosis drug (ATD).

**Discussion:** Multiple risk factors are involved in TB disease. PTB spread occurs through hematogenous, lymphatic, or direct routes. Clinical features and supporting examinations of PTB are non-specific. Diagnosis is often made through incidental histology finding post-TURP. Standard ATD regimen administered based on World Health Organization (WHO) guidelines. Duration can be prolonged due to the suboptimal concentration of prostate tissue.

**Conclusion:** Multidisciplinary approach for extrapulmonary TB is needed. Thorough history taking and a high index of suspicion are important aspects. PTB diagnosis should be considered in patients with recurrent lower urinary tract symptoms refractory to standard therapy in TB endemic areas. (*J Respirol Indones* 2021; 41(3): 207–13)

**Keywords:** tuberculosis (TB), prostate, anti-tuberculosis drug (ATD).

## Laporan Kasus Tuberkulosis Prostat: Temuan Pasca Prosedur Reseksi Prostat Transuretral (*Transurethral Resection of Prostate/TURP*)

### Abstrak

**Latar Belakang:** Prostate tuberculosis (PTB) termasuk salah satu tuberkulosis ekstra paru yang berpotensi memiliki frekuensi komplikasi fatal lebih banyak serta penurunan kualitas hidup yang lebih parah. PTB merupakan entitas penyakit yang sangat jarang dengan prevalensi 2.6% dari seluruh tuberkulosis urogenital (UGTB). Tuberkulosis prostat mungkin merupakan penyakit menular seksual dan dapat mengakibatkan disfungsi seksual.

**Kasus:** Laki-laki, 54 tahun, dengan keluhan retensi urin, disuria, nyeri panggul sejak 1 bulan yang lalu, infeksi saluran kemih berulang sejak 1 tahun yang lalu, dan penurunan berat badan 8 kg dalam 1 bulan. Pemeriksaan fisik menunjukkan pembesaran prostat. Pasien dirujuk ke RSUD Wangaya dengan Benign Prostate Hyperplasia (BPH) suspek malignansi. Setelah menjalani pemeriksaan klinis dan penunjang, pasien menjalani prosedur TURP. Pemeriksaan histopatologi menunjukkan PTB. Pasien kemudian mendapat obat anti tuberkulosis (OAT) kategori I.

**Diskusi:** Berbagai faktor risiko terlibat dalam penyakit TB. Penyebaran PTB terjadi melalui rute hematogen, limfatik, atau langsung. Gambaran klinis dan pemeriksaan penunjang PTB tidak spesifik. Diagnosis seringkali ditegakkan melalui temuan insidental pasca TURP. Regimen OAT standard diadministrasikan berdasarkan pedoman Organisasi Kesehatan Dunia. Durasi pengobatan dapat diperpanjang karena konsentrasi suboptimal ke jaringan prostat.

**Kesimpulan:** Diperlukan pendekatan multidisipliner untuk TB ekstra paru, Anamnesis menyeluruh serta indeks kecurigaan tinggi merupakan aspek yang penting. Diagnosis PTB sebaiknya dipertimbangkan pada pasien dengan gejala saluran kemih bawah berulang yang refrakter terhadap terapi standard pada area endemis TB. (*J Respirol Indones* 2021; 41(3): 207–13)

**Kata kunci:** tuberkulosis (TB), prostat, obat anti tuberkulosis (OAT).

Note: This article was presented and won the first award in the Case Report Poster Presentation Scientific Meeting of Pulmonology and Respiratory Medicine (PIPKRA) 2020, 21-22 February 2020 at Hotel Borobodur, Jakarta

**Correspondance:** Kadek Mien Dwi Cahyani

**E-mail:** miendwicahyani@gmail.com

## INTRODUCTION

Tuberculosis (TB) is a significant health problem contributing to the leading cause of death worldwide. The bacterial infection that causes TB has a wide morbidity spectrum because it can infect multiple organs both in the lung and extra-pulmonary. Extra-pulmonary TB plays an essential role because of the greater frequency of fatal complications and a more severe deterioration in the quality of life.

Globally, TB is in the top rank of the cause of death due to a single infectious agent, namely *Mycobacterium tuberculosis* (*M.tb*). Nearly 90% of cases are found in countries with a high burden of TB, including Indonesia.<sup>1</sup> The most frequent location of TB disease is in the lung parenchyma. Extrapulmonary TB, especially urogenital TB (UGTB), is rarely reported.<sup>1,2</sup> One of the UGTB subtypes, prostate tuberculosis (PTB), is a rare disease. The PTB epidemiology data is still very limited. Mumu et al, reported that PTB was found in only 2.6% of all UGTB. The age range of PTB patients based on the literature is between 35–90 years, with a mean of 65.82 years.<sup>2</sup>

In Indonesia, there is no specific report on the prevalence of PTB. PTB has a significant clinical impact because of several factors, such as PTB may be sexually transmitted diseases; *M.tb* in the ejaculate is found in up to 50% of patients; it can cause infertility, chronic pelvic pain, and reduce sexual function. These various factors contribute to the decline in the quality of life.<sup>3</sup> In addition, PTB that is late diagnosed has the potential to have a distant spread. PTB causes significant morbidity.

The spread of PTB can occur hematogenous, lymphatic or direct route.<sup>4</sup> Several predisposing factors include previous TB infection, immunodeficiency conditions, low socioeconomic conditions, and a history of BCG vaccination.<sup>5</sup> However, PTB in the early stages is very complex due to a lack of pathognomonic symptoms and low excretion of bacteria. The majority of cases were not suspected at the beginning of the patient's visit to a health service center. Clinical manifestations can include the lower urinary tract, urinary incontinence,

urinary tract infection; urinary retention; and low back pain.<sup>2</sup> However, these symptoms are usually refractory to standard treatment regimens, and PTB are easily underdiagnosed. Therefore, it is not surprising that patients are often treated as a common urinary tract infection.

Non-specific clinical features, low case finding frequency, and no specific guidelines globally make early detection difficult. Almost all cases of PTB are incidental findings or at autopsy. It is also known that the clinical presentation of PTB can mimic a malignant process.<sup>6</sup> The diagnosis of PTB is generally confirmed by histopathology. The authors report cases of prostate tuberculosis that were found after the Transurethral Resection of The Prostate (TURP) procedure.

## CASE

Male, 54 years old, came to Wangaya Hospital and was referred from Siloam Hospital, Labuan Bajo. The patient presented with urinary retention, urinary incidence, dysuria, and back pain one month before admission. The patient also experiences a weight loss of 8 kg in the last 1 month. The patient often had similar symptoms and was treated as a urinary tract infection in the last 1 year ago. The patient denied prolonged cough, coughing up blood, cold sweat, shortness of breath, or chest pain.

Other symptoms including nausea, a history of unexplainable fever, malaise, and decreased appetite. Patients often experienced similar complaints and have been treated for urinary tract infections one year ago. The patient has never received immunizations and his occupation was a farmer. The patient's family member is an active smoker, smoking around one pack per day. Similar symptoms and family history of TB disease were denied.

From the physical examination, the patient was moderately ill, compos mentis, with vital signs as following blood pressure 120/80 mmHg, heart rate 97x/minute, respiratory rate 18x/minute, axillary temperature 36.7°C, SpO<sub>2</sub>=98% of room air, and pain scale 3. Physical examination of the lungs obtained

symmetrical inspection, normal palpation of vocal fremitus in both lung fields, percussion obtained resonance in both lung fields, and auscultation of bronchovesicular breath sounds at the apex of the right and left lungs, no rhonchi or wheezing were found. The digital rectal examination found a palpable prostate lump with solid rubbery consistency and the fingertips cannot touch the upper end of the prostate lump (enlarged size >4cm).

The patient had brought several results of the supporting examinations from the Siloam Hospital Labuan Bajo. The complete blood cells examination found an increase in white blood cells (12.04) The urinary sediment examination found high erythrocytes concentration, increased leucocytes (16–19) and squamous epithelial cells (8–12), and also positive for bacteria. The ultrasound examination found an enlarged prostate.

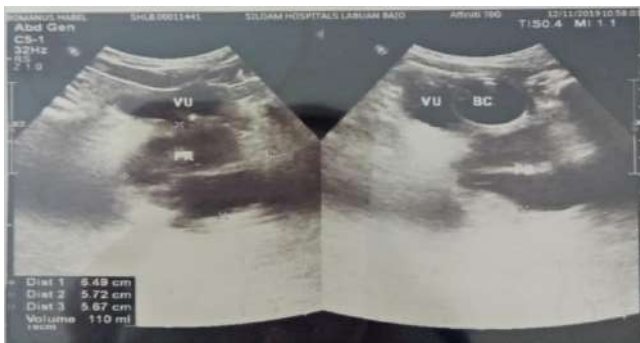

Figure 1. Prostate ultrasound showing an enlarged size with a volume of 110 ml, flat surface.

Based on clinical manifestations and investigations, the patient was diagnosed with BPH with a differential diagnosis of prostate malignancy. The patient was then further evaluated. The complete blood count found an increase in neutrophils (78.1%). The prostate-specific antigen (PSA) was normal (0.9 ng/mL). The PA chest X-ray (Figure 2) shows fibroinfiltrates in both lung fields and a minimal left pleural effusion. The patient then underwent TURP procedure. The prostate specimen was sent for histopathological examination.

The results of histopathological examination of prostate tissue showed granulomatous features with caseous necrosis and multinucleated giant cells (*Langhan's type*), suggesting prostate tuberculosis.

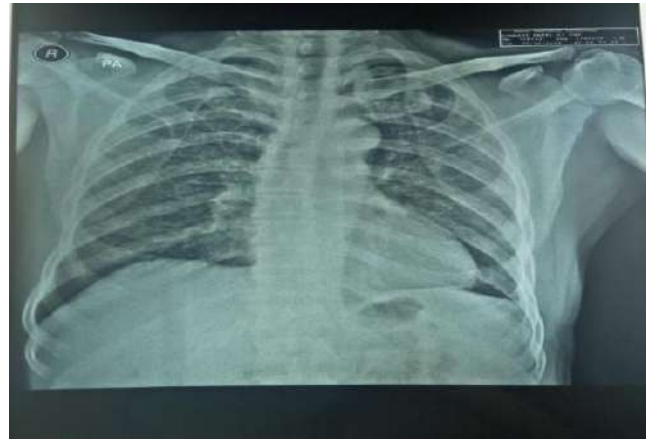

Figure 2. The PA chest X-ray at Wangaya Hospital. Fibroinfiltrates were seen in both lung fields and a minimal left pleural effusion also can be seen.

The patient was then consulted to the pulmonary clinic. Based on the history, a similar history with the first treatment was obtained. Physical examination found no significant abnormalities.

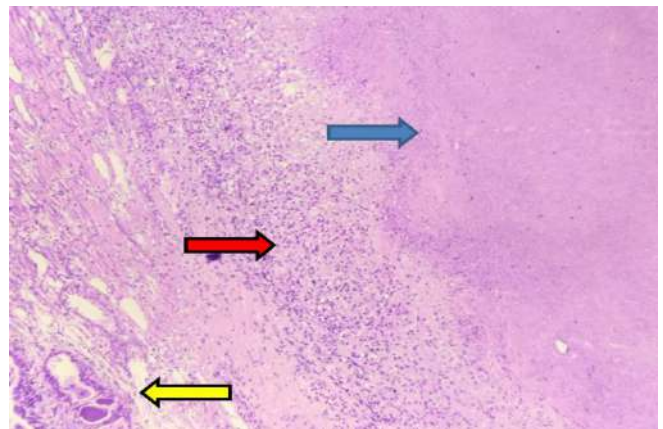


Figure 3. Histopathology results at Wangaya Hospital. Blue arrows show areas of caseous necrosis. Red arrows show granulomas with lymphocytes and plasma cells surrounding caseous necrosis. The yellow arrow indicates a normal prostate gland.

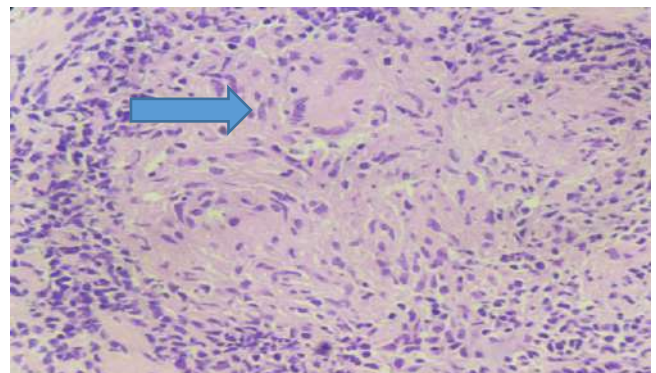


Figure 4. Patient histopathology. The blue arrow shows *Langhan's giant cell type*.

A rapid molecular test with Xpert MTB/RIF was carried out and the *M.tb* was not found. The HIV test result was non-reactive. The patient's diagnosis was

pulmonary tuberculosis (with prostate tuberculosis). The patient was then treated with category I ATD management for 6 months with 2 (HRZE)/ 4 (HR)<sub>3</sub>.

## DISCUSSION

The epidemiological data for tuberculosis in the prostate (PTB) is still very limited. This UGTB subtype is the rarest with primary PTB autopsy findings of only 1%.<sup>7</sup> Research by Kuchalvenya et al,<sup>8</sup> found that PTB contributed 32.7% of all male genital TB (epididymal TB, epididymal-orchitis, prostate, seminal vesicles, and penis). The demographic characteristics of age, socioeconomic, and localization of our TB patients are consistent with previous reports of increasing the risk of *M.tb* infection.

Based on the literature, the age of PTB patients varies from 26 to 90 years.<sup>2</sup> Yddoussalah et al reported that all PTB patients who had a low socioeconomic level came from rural areas.<sup>9</sup> This condition is one of the risk factors for disease transmission. Several other determinants that increase the probability of TB disease include immunodeficiency conditions, alcohol and substance abuse, smoking, homelessness, poor housing, pneumoconiosis, genetics, and vitamin deficiency.<sup>5</sup>

In addition to socioeconomic status, patients have other risk factors that increase the risk of TB disease, which is a history of BCG vaccination. World Health Organization (WHO) guidelines stated that the BCG vaccine is the only vaccine for TB prevention. The protection obtained from the BCG vaccine varies from 44–99%. WHO recommends routine administration of the BCG vaccine in countries with high TB burden, including Indonesia.<sup>10</sup> However, the percentage of BCG coverage in Indonesia based on Riskesdas 2013 was only 87.6%.<sup>11</sup> Our patient is an example that illustrates that vaccine coverage is not yet optimal, causing TB disease.

The classification of TB is based on location, including pulmonary and extrapulmonary TB. If there is pulmonary and extrapulmonary TB together, it is classified as pulmonary TB. In this patient, lung involvement was found from the chest x-ray.

Epidemiological data on pulmonary tuberculosis and PTB have been published. PTB patients reported having active TB from other locations as much as 33% (mostly lung) and a previous history of TB in 38.7%.<sup>3</sup> These data are supported by the theory that PTB is almost always secondary to *M.tb* infection in the lungs or kidneys. However, the primary focus may occur undetected in the majority of cases. Primary focus reactivation may also occur in individuals with a history of TB.<sup>12</sup>

The prostate can be infected with *M.tb* via the hematogenous, lymphatic, or direct route of transmission.<sup>4</sup> Sexual transmission of *M.tb* has been reported because the pathogen *M.tb* is found in semen, but it is rare. The pathogenesis of *M.tb* in humans has been extrapolated from animal models. However, the exact sequence of events following primary human infection by *M.tb* remains unclear. Certain individuals naturally have innate immunity to eradicate *M.tb* and are resistant to *M.tb* infection. Following primary infection acquired by inhalation or ingestion, *M.tb* bacilli replicate locally in the tissues and stimulate a complex immune response, resulting in the elimination or formation of primary granulomas (primary Ghon foci). Primary TB lesions can be found in various organ systems, most commonly in the lungs.<sup>12,13</sup>

Uncontrolled replication of *M.tb* increases the chance of active infection and distant spread. Clinical features take between 12 months–2 years post-primary infection to manifest because of the slow *M.tb* replication rate and intracellular location in macrophages. The latent period between the first pulmonary infection and presentation of the UGTB ranges from 1–50 years, 22 years.<sup>6,14,15</sup> Therefore, PTB patients are rarely seen at a young age.

Based on previous exposure, tubercular infection of the prostate causes chronic granulomatous inflammation with central caseous necrosis,<sup>12</sup> as seen in Figure 3. Furthermore, fibrosis or cavity formation occurs in extreme cases. The disease can spread rapidly and result in glandular destruction, reducing semen volume.<sup>7</sup> Advanced tubercular lesions show the perineal sinuses and are palpable on palpation of the prostate, i.e. fluctuating

bilateral enlargement and tender zones are found. In addition, dissemination of *M.tb* may perforate into the urethra, bladder, rectum, scrotum, perineum, and peritoneal cavity.<sup>16</sup> Patient complaints generally arise when prostate lesions reach an advanced stage.

The majority of patients present with signs of lower body obstruction, which is symptoms of an enlarged prostate. Common presentations are irritable urination, hemospermia, perineal pain, dysuria, and sterile pyuria. One case series noted that none of the patients presented with respiratory symptoms, and only one patient had a history of TB. Other characteristics that can be found include an increased frequency of urination, nocturia and hematuria. Physical examination focuses on finding abnormalities of the internal genital organs. Digital rectal examination may reveal an increase in prostate volume, elastic consistency, hardness, or nodularity.<sup>15,17</sup> It can be seen that the patient's clinical manifestations are not pathognomonic. Thus, diagnosis and management require a multidisciplinary team.

The patient, in this case, experienced a weight loss of 8 kg in the last one month, symptoms of prostate obstruction in the form of LUTS, and recurrent UTI for the last one year without clinical resolution. Non-specific constitutional symptoms of TB such as fever, weight loss, or night sweats are uncommon. If found, it indicates concomitant TB outside the urogenital tract, such as pulmonary TB. Kuchalvenya et al stated that the risk factors for UGTB include recurrent UTI that is resistant to standard therapy and UTI with persistent dysuria. Supporting statistics show the total prevalence of UGTB among UTI patients with poor antibacterial therapy results is 25.8%. Comorbid UTI was diagnosed in 65.1% of the UGTB.<sup>3,6</sup> The most common condition that masked the diagnosis of PTB was chronic prostatitis with recurrent UTI. Therefore, a thorough history and a high index of suspicion are important aspects of early detection. Chronic prostatitis with LUTS symptoms and recurrent UTIs refractory to standard antibiotics should raise suspicion of PTB, especially in TB endemic areas such as Indonesia.

On investigations, laboratory findings are less specific. Urinalysis and urine culture may show normal results due to the low excretion of *M.tb* in the urine. Examination of urine with *Ziehl Neelsen* (ZN) staining for acid-resistant bacteria has high specificity but low sensitivity of 50% for UGTB diagnosis. The culture of urine samples for detection of *M.tb* is positive in only 30–40% of cases. Thus, negative culture reports should be followed by *polymerase chain reaction* (PCR) studies. The advantages of PCR are that it can give faster results (within 24–48 hours) and only requires finding a few bacilli for detection. This examination has a sensitivity of 94.3% and a specificity of 85.7%.<sup>15,18</sup> However, the shortcomings of PCR are limited availability and high cost, thus it is not routinely used in health centers in Indonesia. Meanwhile, *prostate-specific antigen* (PSA) levels varied from normal (<4.0 ng/ml) to elevated. If the PSA level is elevated, the diagnosis of prostate cancer cannot be ruled out.<sup>7,8,15,18</sup>

Important imaging diagnostic modalities for PTB include X-rays, ultrasonography (USG), especially trans-urethral ultrasonography (TRUS), computed tomography scan (CT scan), and magnetic resonance imaging (MRI). The chest X-ray is one of the crucial initial investigations because a patient with PTB can also have active pulmonary TB simultaneously, as in this patient. Ultrasound images at early stage PTB may not show changes. Prostate TRUS examination can show the feature of an enlarged irregular glandular area with a solitary hypoechoic zone (rare) or multiple irregular zones of varying size.<sup>15,18</sup> TB lesions are typically located in the periphery and lateral lobes of the prostate.<sup>3</sup>

Imaging examination can aid the diagnostic, but there are still possibilities of overlapping with other pathological lesions of the prostate. The clinical and supporting data above remain devoid of pathognomonic characteristics and may even mimic prostate malignancy or chronic prostatitis due to other pathogens.<sup>18</sup> Due to the unusual presentation, almost all cases of PTB were found to be incidental in biopsy specimens from TURP procedure.<sup>15,17</sup> Histopathological examination of PTB shows a typical caseous granuloma consisting of a collection of



epithelioid cells, macrophages, lymphocytes, plasma cells, Langhans giant cells, fibroblasts with collagen, and characteristics of central caseous necrosis.<sup>6,17,18</sup>

The standard anti-tuberculosis drug (ATD) regimen based on WHO recommendations remain the treatment of choice. The patient in this case report is newly diagnosed with pulmonary TB and PTB. The standard types of ATD in pulmonary TB are isoniazid (H), rifampicin (R), pyrazinamide (Z), and ethambutol (E) regimens. The duration of ATD is given for six months with a regimen of 2(HRZE)/4(HR)<sub>3</sub>. The administration doses are listed in Table 1 in the form of a fixed-dose combination (FDC). In UGTB, the duration of ATD in several studies is 6–12 months. This duration may be extended depending on clinical response, disease severity and immunodeficiency conditions. Certain studies even suggest a longer duration of ATD, namely for two years.<sup>15</sup>

The challenge of prostatitis therapy from various etiologies is that only a few antibacterial agents are distributed to the prostate tissue and reach adequate concentrations at the site of infection. These agents include fluoroquinolones, macrolides, tetracyclines and trimethoprim. Standard ATD therapy, in addition to rifampicin, has suboptimal concentrations in prostate tissue. A study suggested using ofloxacin because it has a wide range of antibacterial activity, including a bactericidal effect against *M.tb*, making it the optimal drug for PTB. Other reports suggest streptomycin and kanamycin should not be used for TB. The same study also recommended ofloxacin and levofloxacin as fluoroquinolones suitable for UGTB. Amoxicillin/clavulanate should be prescribed together with meropenem or imipenem because it potentiates anti-TB effects. The administration of amikacin, streptomycin, and kanamycin is contraindicated because it induces the transformation from TB inflammation to fibrosis.<sup>3</sup> However, there are no other data to support this claim, so further research is needed.

Some complications that can occur in PTB that are not handled properly are strictures, fistulas, infertility, and sexual dysfunction.<sup>15</sup>

**Table 1.** Dosage of FDC ATD Category 1 (2 (HRZE)/ 4 (HR) 3)<sup>19</sup>

Weight	Daily intensive phase HRZE (150/75/400/275) for 56 days	Continuation phase 3 times a week RH (150/75) for 16 weeks
30–37 kg	2 tablet 4FDC	2 tablet 2FDC
38–54 kg	3 tablet 4FDC	3 tablet 2FDC
55–70 kg	4 tablet 4FDC	4 tablet 2FDC
≥71 kg	5 tablet 4FDC	5 tablet 2FDC

Note: FDC=fixed-dose combination

## CONCLUSION

Tuberculosis contributes to the top ten causes of death worldwide. Prostate tuberculosis is very rare with limited epidemiological data. *Mycobacterium tuberculosis* infection of the prostate can occur in the hematogenous, lymphatic, or direct route. Non-specific clinical features and supporting modalities of PTB. A multidisciplinary approach is needed in the diagnosis and management of TB. A thorough history and a high index of suspicion are important aspects. The diagnosis of PTB should be considered in patients with both lower urinary tract symptoms and recurrent urinary tract infections (UTIs) refractory to standard therapy in TB endemic areas. The majority of PTB diagnoses were confirmed by histopathology incidentally after the TURP procedure. The standard anti-tuberculosis drug (ATD) regimen based on World Health Organization (WHO) recommendations remains the treatment of choice. The duration of ATD can be extended due to suboptimal concentrations of the prostate tissue. Complications that can occur include strictures, fistulas, infertility, and sexual dysfunction.

## REFERENCE

1. World Health Organization. Global Tuberculosis Report 2019. Geneva: World Health Organization; 2019.
2. Hossain MAMA, Banu S, Karim MM, Rahman MT. Tuberculous Prostatitis is Rare in Prostate Cancer Patients in Bangladesh. *Bioresearch Commun.* 2016;2(2):281–4.
3. Kulchavenya E, Naber K, Johansen TEB. Urogenital Tuberculosis: Classification, Diagnosis, and Treatment. *Eur Urol Suppl.*

- 2016;15(4):112–21.
4. Khan FY. Review of Literature On Disseminated Tuberculosis with Emphasis On The Focused Diagnostic Workup. *J Family Community Med.* 2019;26(2):83–91.
  5. Duarte R, Lönnroth K, Carvalho C, Lima F, Carvalho ACC, Muñoz-Torrico M, et al. Tuberculosis, social determinants and co-morbidities (including HIV). *Pulmonology.* 2018;24(2):115–9.
  6. Muneer A, Macrae B, Krishnamoorthy S, Zumla A. Urogenital tuberculosis - epidemiology, pathogenesis and clinical features. *Nat Rev Urol.* 2019;16(10):573–98.
  7. Ratkal JM. Primary prostatic tuberculosis: A rare form of genitourinary tuberculosis. *African J Urol.* 2015;21(2):142–3.
  8. Kulchavenya E, Kholtohin D, Shevchenko S. Challenges in urogenital tuberculosis. *World J Urol.* 2020;38(1):89–94.
  9. Yddoussalah O, Touzani A, Karmouni T, Elkhader K, Koutani A, Attya AI, et al. Isolated Prostate Tuberculosis. Report of 3 Case. *ARC J Urol.* 2017;2(4):22–5.
  10. Santé, Organization WH. BCG vaccines: WHO position paper. *Wkly Epidemiol Rec.* 2018;93(08):73–96.
  11. Kementrian Kesehatan RI, GAVI. Buku Ajar Imunisasi. Mulati E, Isfan R, Royati M O, Widyaningsih Y, editors. Jakarta: Kementerian Kesehatan Republik Indonesia; 2015. 1–80 p.
  12. Hunter RL. Tuberculosis as a three-act play: A new paradigm for the pathogenesis of pulmonary tuberculosis. *Tuberculosis (Edinb).* 2016;97:8–17.
  13. Rao M, Ippolito G, Mfinanga S, Ntoumi F, Yeboah-Manu D, Vilaplana C, et al. Latent TB Infection (LTBI) - Mycobacterium tuberculosis pathogenesis and the dynamics of the granuloma battleground. *Int J Infect Dis.* 2019;80S:S58–61.
  14. Joneja U, Short WR, Roberts AL. Disseminated tuberculosis with prostatic abscesses in an immunocompromised patient-A case report and review of literature. *IDCases.* 2016;5:15–20.
  15. Verma A, Singh A, Kishore K, Kant S. A rare presentation of disseminated tuberculosis: Prostatic abscess. *Indian J Tuberc.* 2017;64(4):330–3.
  16. Meena LS, Ansari R. Pathogenic Aspects of Genito-Urinary Tuberculosis in Males and Females. *J Mol Biol Biotechnol.* 2017;2(1).
  17. Aziz EM, Abdelhak K, Hassan FM. Tuberculous prostatitis: mimicking a cancer. *Pan Afr Med J.* 2016;25:130.
  18. Ururahy EK, Fonseca N, Kaufmann OG, Ribeiro De Sousa Leão L, Franco Tridente C, Yamauchi FI, et al. Incidentally detected tuberculous prostatitis with microabscess. *Int Braz J Urol.* 2018;44(2):397–406.
  19. Kementrian Kesehatan Republik Indonesia. Peraturan Menteri Kesehatan Nomor 67 Tahun 2016. Jakarta: Kementrian Kesehatan Republik Indonesia; 2016.